

## DIGITAL IMPRESSIONS FOR THE FABRICATION OF AESTHETIC CERAMIC RESTORATIONS: A CASE REPORT

Steven Glassman, DDS\*

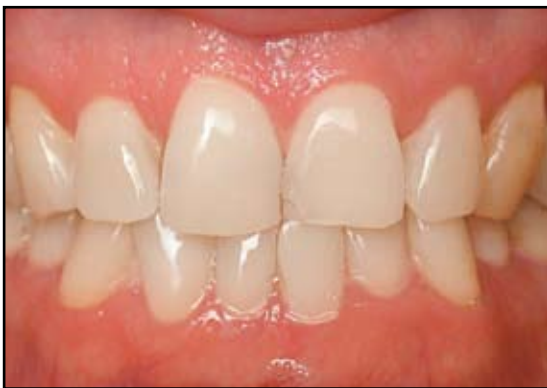Impressions for fixed prostheses, despite advances in the materials themselves, contain many variables and have consistently represented a challenge for both the restorative dentist and the dental laboratory. Many impressions are problematic (eg, unclear margin reproduction, distortion from improper handling prior to pouring, incomplete registration of finish lines, oral fluid contamination, tray movement during transfer) to some extent, and proper handling is fundamental to restorative success.<sup>1-3</sup>

Even when the practitioner correctly performs tooth preparation and forwards detailed impressions and bite registrations to the dental laboratory for restoration fabrication, additional chairtime can be required at the seating appointment for final adjustment of contacts and/or occlusion. In the author's opinion, should chairside adjustment consume more than five minutes, then

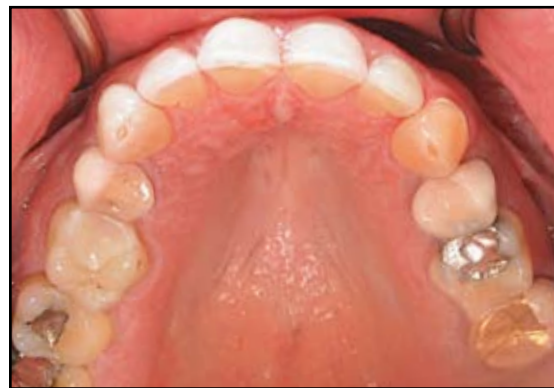the process being applied is most likely inefficient and expensive to the practice.

It is also the author's experience that dental technicians may compensate for perceived distortions in the impression by adding spaces to the opposing models and adjacent teeth. This can result in a restoration that is misaligned and has very light or open contacts. Returning restorations to the laboratory for remakes, remounts, and reglazes can be expensive to the practice and may result in added overhead expense.<sup>4</sup>

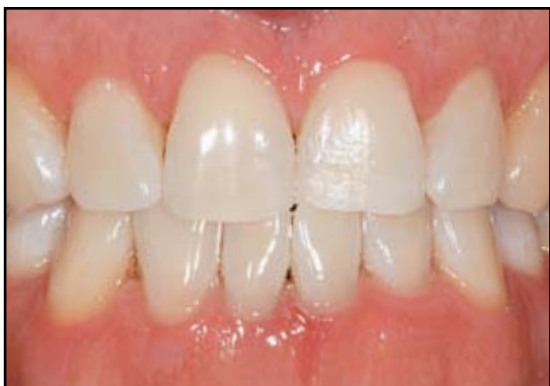From a cost basis, the practice of using full-arch impressions may reach up to 30 dollars to 40 dollars for a stock tray, and 15 dollars to 20 dollars for a custom tray. Such a cost is for a single impression alone and does not factor in the remakes that clinicians may have to perform if the first impression is inadequate. Clinicians may often be unaware of the true cost of making



**Figure 1.** Preoperative facial view demonstrating a lack of occlusal harmony and aesthetics.



**Figure 2.** Preoperative view of the patient, who had his premolars removed years prior during adolescent orthodontics.

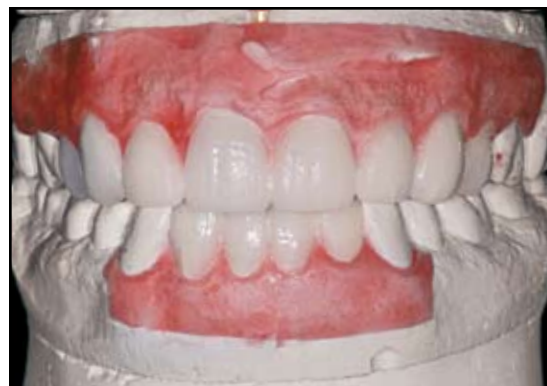

**Figure 3.** View of the patient's dentition following the completion of orthodontic therapy (ie, Invisalign, Align Technology, Santa Clara, CA) to relieve crowding of the mandibular incisors.

impressions for laboratory-fabricated restorations and the time and money necessary to seat a clinically acceptable, aesthetic restoration.

### The Support of CAD/CAM Technology

Computer-assisted design / computer-aided manufacturing (CAD/CAM) applies mechanical- and laser-based scanning technology in the development of accurate, well-fitting dental restorations, and it has become a well-accepted tool in the field. Digital dental technologies such as CAD/CAM, once used for the scanning and milling of durable restorative materials (eg, restorations, abutments, frameworks),<sup>5,7</sup> now support the impression process as well. Based on a laser scanning protocol known as "parallel confocal" imaging, the iTero digital impression system (Cadent, Carlstadt, NJ) eliminates the need for conventional impression materials (eg, trays, putties, wash materials). The system's laser scanners capture a three-dimensional image of a prepared tooth and the opposing dentition which, when combined with a digital bite registration, are used to produce a three-dimensional image.<sup>8</sup> As the clinician has a magnified view of the final impression displayed chairside, any issues regarding moisture or isolation are readily apparent and can be immediately corrected.<sup>9</sup> When proper tissue management is used to enable visualization of



**Figure 4.** A diagnostic waxup was created from mounted casts and would enable the fabrication of a putty matrix for chairside tooth reduction.

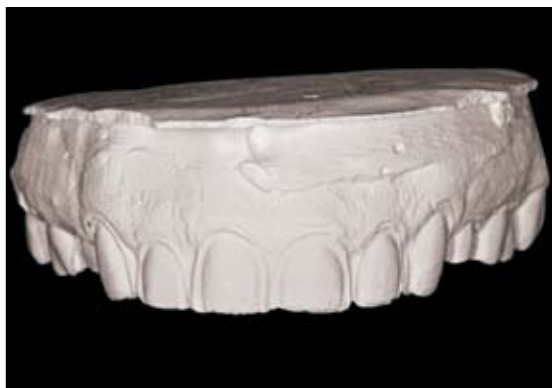the finish line, both supra- and subgingival preparations can be recorded with accuracy.<sup>10</sup> This system functions similarly to the CEREC 3D (Sirona Dental Systems, Charlotte, NC) yet does not require imaging powder on the prepared dentition in order to record the desired intraoral condition.

The resulting computer file is archived in the patient's permanent record and forwarded to the system's manufacturer, where the digital scan is used in the fabrication of a precise working/master model.<sup>8</sup> This physical model is forwarded to the clinician's preferred dental laboratory, where the final ceramic restoration is fabricated and then returned to the practitioner for try-in, cementation, and finishing.

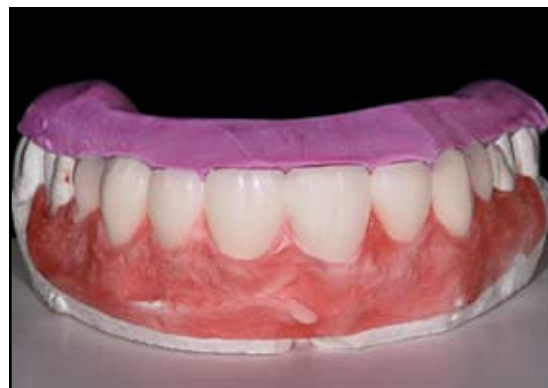As demonstrated in the case presentation that follows, this technology enables the clinician and laboratory technician to deliver accurate, well-fitting restorations for a more efficient clinical workflow and a more seamless patient experience.

### Case Presentation

A male patient presented for aesthetic enhancement following the completion of orthodontic treatment (ie, Invisalign, Align Technology, Santa Clara, CA), which relieved the crowding of the mandibular incisors, provided a more stable overbite/overjet relationship, and



**Figure 5.** Prepared model in the dental laboratory indicating the amount of tooth reduction that would be necessary for the pending maxillary restorations.

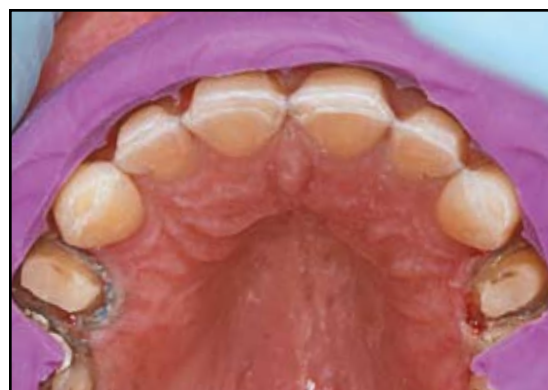

**Figure 6.** A reduction matrix was created from the diagnostic waxup and would be used chairside to guide tooth preparation.

removed an existing edge-to-edge bite (Figure 1). All four first premolars had been extracted prior to conventional orthodontia when the patient was in his early teens (Figure 2).

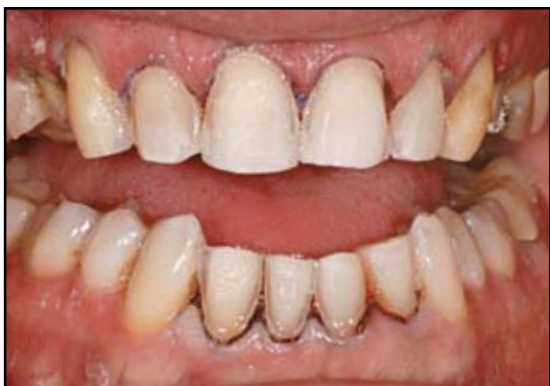The original treatment plan included this orthodontic therapy, tooth whitening, and subsequent restoration of teeth #4(15) through #13(25). Teeth #4 and #13 were to be restored with all-ceramic zirconia crowns to replace opaque porcelain-fused-to-metal restorations (PFMs). Teeth #6 through #11, in addition to #23 through #26, were to be conservatively restored with feldspathic porcelain veneers. Following completion of orthodontic treatment (Figure 3), a diagnostic waxup was created from mounted casts (Figure 4). Kois facebow and centric relation bite records were obtained in order to mount the case as precisely as possible and capture occlusal and dentofacial information. The mounted models, along with a series of digital photographs, were forwarded to the dental laboratory in order to create the initial diagnostic waxup. The completed waxup was returned for inspection along with a reduction matrix, prepared models, and a provisional template (Figures 5 and 6).

Following the administration of anesthetic, the relevant case information (ie, patient name, laboratory, number of teeth, type of restoration, material, stump, and shade) was entered into the computer terminal for the

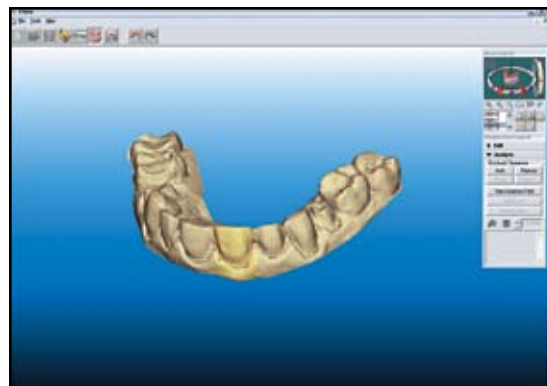


**Figure 7.** Clinical application of the tooth reduction guide to ensure sufficient space would exist for the zirconia full-coverage crown restorations.

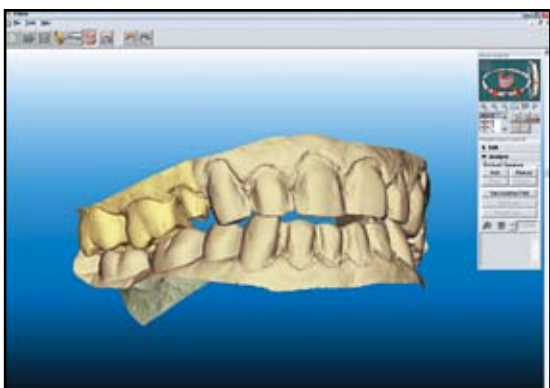digital impression scanner (ie, iTero, Cadent, Carlstadt, NJ). The preexisting PFMs were removed, and the maxillary teeth were provisionalized after tooth reduction was performed. Tooth preparation for the porcelain veneers was performed according to the reduction guides (Figure 7). Since the teeth were in proper alignment following orthodontic treatment, the preparations were confined to the tooth enamel, with a reduction of 0.3 mm to 0.5 mm on the labial surfaces and approximately 0.1 mm on the incisal edge. Retraction cord (ie, Ultrapak, Ultradent Products, South Jordan, UT) was placed subgingivally (Figure 8), which allowed the clinician to refine the preparations without iatrogenic damage to the gingiva. Following refinement of the chamfer



**Figure 8.** Facial view of the prepared dentition following the insertion of the gingival retraction cord.



**Figure 10.** The digital impression would be used to create polyurethane models on which the ceramic restorations would be fabricated.



**Figure 9.** View of the digital impression chairside enabled immediate verification of the preparation design.

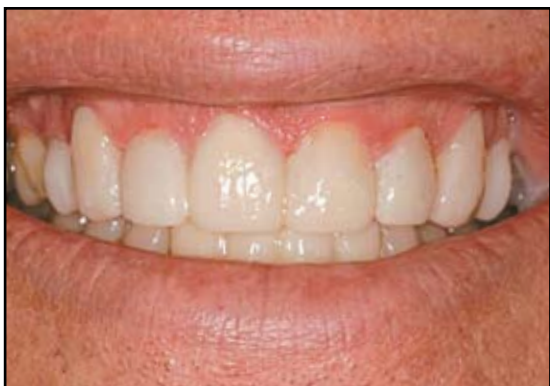preparations, a second cord was placed and allowed to set for five minutes. A single retraction cord was placed at the veneer preparations, again allowing the clinician to refine and visualize the margins. Since the patient presented with a relatively high lip line, the author elected to keep the margins slightly subgingival. Following an additional five-minute set period, the scanning procedure was initiated.

Scanning for the digital impression was performed with the camera in contact or slightly away from the teeth. Voice prompts indicated when individual tooth scanning and opposing arch scans were necessary. A functional bite registration was taken with the teeth in centric occlusion by positioning the camera horizontally.

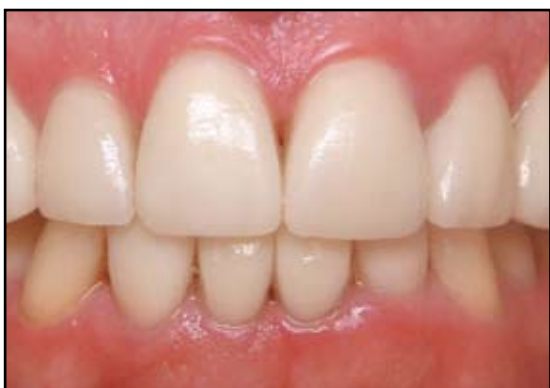If any blood or oral fluids seeped into the preparation, the operator removed the camera and allowed the assistant to blow or blot the fluids from the area prior to image capture. If the operator moved the camera during image capture, the digital impression system prompted the author to rescan that particular tooth before proceeding to the next. The scanning process for the entire 12-unit case was completed in less than seven minutes for both arches (Figures 9 and 10).

The patient was provisionalized (Figure 11) and the case was then forwarded digitally to the manufacturer, where the digital information was analyzed. The three-dimensional scan was digitally forwarded from there to the laboratory for approval. Once the scan was deemed acceptable, the digital information was sent to a milling machine, where polyurethane models were created. The finished, articulated models were forwarded to the dental laboratory for fabrication of the definitive restorations. The mandibular veneers were fabricated with feldspathic porcelain, and the full-coverage crowns were fabricated from zirconia (ie, Lava, 3M ESPE, St. Paul, MN).

Throughout this process, the patient was given time to evaluate the aesthetics, phonetics, and function delivered by the provisional restorations. Any necessary adjustments were made and communicated to the laboratory.



**Figure 11.** The provisionalization phase enabled the patient to evaluate aesthetics, function, and phonetics while the definitive restorations were fabricated.



**Figure 12.** Immediate postoperative facial view of the bonded restorations, demonstrating enhanced aesthetics and symmetry.

On the seating appointment, the patient was anesthetized and the provisional restorations were removed. The preparations were cleaned via intraoral sandblasting and chlorhexidine. The definitive restorations were tried in to evaluate fit, contact area, occlusion, and aesthetics. The case was tried in with water-soluble gel (eg, RelyX, 3M ESPE, St. Paul, MN), and it was decided that a clear paste would be acceptable. The try-in gel was removed and the veneers were prepared with a phosphoric acid etch, rinsed, cleaned, and coated with a silane material. Following tissue retraction and hemostasis, the veneers and crowns were adhesively bonded (ie, Optibond Solo, Kerr Corporation, Orange, CA; RelyX, 3M ESPE, St. Paul, MN) in place. Excess cement was removed with use of curved scalpel and discs, and the

occlusion was verified. The entire seating appointment, from removal of the provisional restorations to final polishing, was performed in just 10 minutes—including all chairside adjustment (Figure 12). The patient was rescheduled for one more follow-up appointment to finalize the occlusion and aesthetics.

## Conclusion

The fabrication of a single restoration involves multiple processes in the clinical and laboratory setting, and each introduces a new variable that will influence the delivery of a well-fitting, aesthetic, biologically acceptable result. In the author's opinion, the use of digital impressions (ie, iTero, Cadent, Carlstadt, NJ) can provide efficiencies and accuracy for the clinician, dental technician, and patient. As demonstrated herein, the treatment process ran efficiently, saving valuable clinical and patient time. As a result of the accuracy achieved through the parallel confocal technology, minimal adjustment was required to correct contacts and occlusion, and the results were highly aesthetic and functional.

## References

1. Survey respondents are upbeat and optimistic about the state of our industry. *Lab Management Today* 2000;16:9-13.
2. Christensen GJ. The state of fixed prosthodontic impressions: Room for improvement. *J Am Dent Assoc* 2005;136(3):343-346.
3. Shillingburg HT Jr, Hobo S, Whitsett LD, et al. Impressions. In: *Fundamentals of Fixed Prosthodontics*, 3rd ed. Quintessence Publishing, Carol Stream, IL:281-307.
4. Pitel ML. Successful Impression Taking. First Time. Every Time. Heraeus Kulzer; Armonk, NY:BB3.
5. Mormann WH, Brandestini M, Lutz F, et al. Chairside computer-aided direct ceramic inlays. *Quint Int* 1989;20:329-339.
6. Duret F, Blouin J, Duret B. CAD-CAM in dentistry. *J Am Dent Assoc* 1998;117:715-720.
7. Touati B, Etienne JM, Van Dooren E. Esthetic Integration of Digital-Ceramic Restorations. Montage Media Corporation, Mahwah, NJ:2008.
8. Lomke MA. Clinical applications of dental lasers. *General Dentistry* 2009. In press.
9. Digital impressions challenge conventional impressions. *CRA Newsletter* 2007;31(11):3-4.
10. Henkel GL. A comparison of fixed prostheses generated from conventional vs digitally scanned dental impressions. *Compend Curr Educ Dentistry* 2007;28(8):422-431.

**\*\*Private practice, New York, NY.**