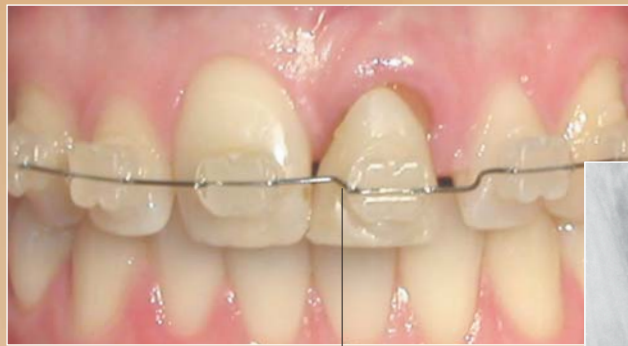
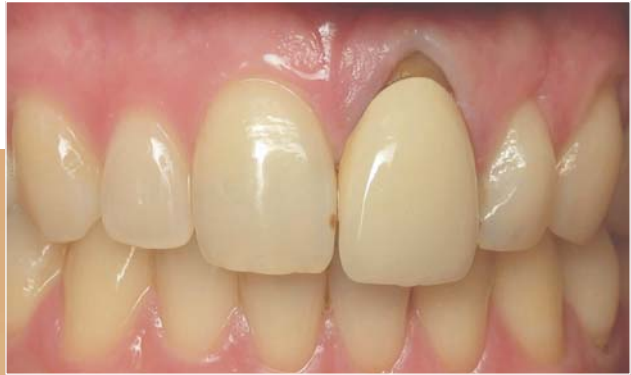
Aesthetic Tissue Response Using a Multidisciplinary Treatment Protocol for Implant Placement

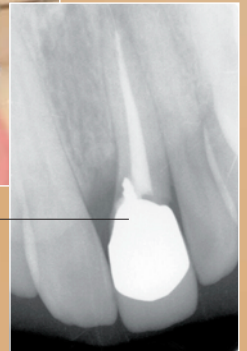


Steven Glassman, DDS*

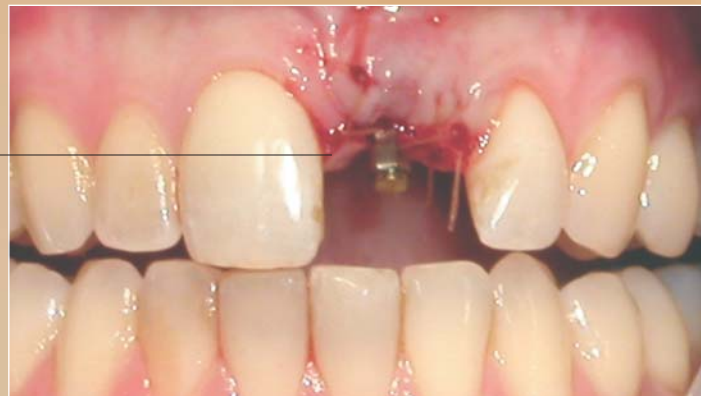- Patient education was critical to ensure acceptance of a sound, predictable approach using an implant restoration to replace the existing crown.
- A multidisciplinary team consisting of a restorative dentist, orthodontist, periodontist, and laboratory technician would use a zirconia CAD/CAM implant abutment (SIMPL, Town & Country Dental Studios) to achieve a harmonious natural result.
- Tooth #9 would be orthodontically extruded to enhance the amount of available bone and soft tissue. A porcelain veneer would be placed on tooth #8, and an all-ceramic material chosen as a matching restorative material over the zirconium abutment.



Provisional restoration on tooth #9 and orthodontic extrusion

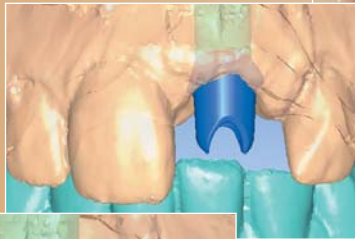
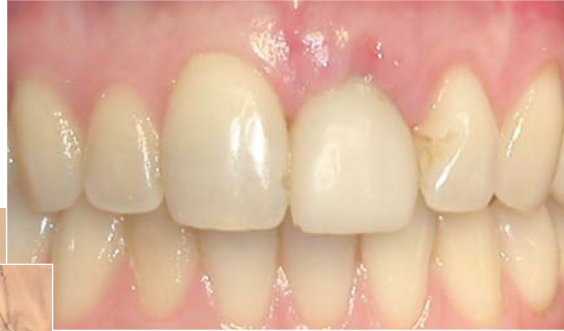
Note short endodontic post and possible root fracture

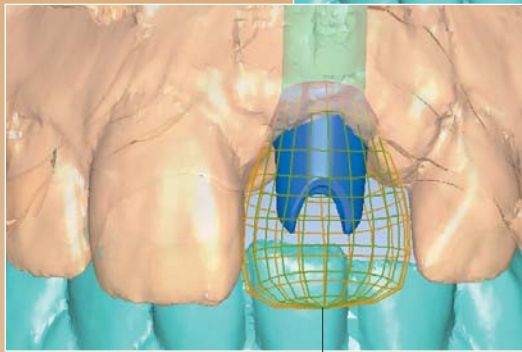


Implant uncovering at six months and connection of temporary abutment

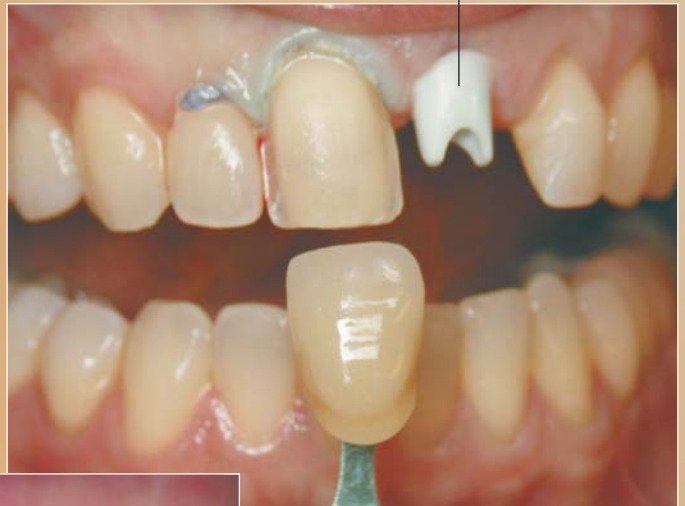Steven Glassman, DDS



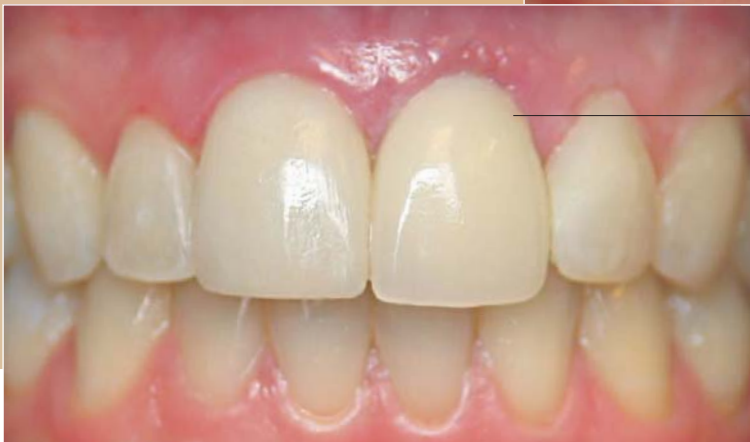Zirconium abutment placed after three weeks of healing and preparation of adjacent central incisor



The CAD/software was used to ensure optimal restorative design



Immediate postoperative appearance



* Private practice, New York, NY.

Glassman Dental Care
160 West End Avenue, #1-R
New York, NY 10023
Tel: 212-787-4860
Email: steve@glassmandentalcare.com